

Intradural And Intramedullary Melanotic Schwannoma of The Lumbar Spine, After Spinal Anesthesia. A Case Report

Luiz Eduardo Imbelloni, MD, PhD^{1*}  , Claudia Helena Ribeiro da Silva, MD² , Alexandra de Vasconcelos Vieira, MD³ , Pedro Marcos Silva e Gonçalves, MD⁴  , Larissa Magalhães Lopes, MD⁵ 

¹Co-responsible for CET-SBA Hospital Clínicas Municipal de São Bernardo do Campo, SP, Brazil.
INCA Senior Researcher, Rio de Janeiro, RJ, Brazil.

²Master in Health Sciences from the Teaching and Research Institute of Santa Casa de Belo Horizonte
Responsible for CET-SBA Hospital Felício Rocho, Belo Horizonte, MG, Brazil

³Coordinator of the Medical Residency Program at HU Contorno at Unimed, Belo Horizonte, MG, Brazil

⁴Master in Sciences Applied to Surgery and Ophthalmology, Faculty of Medicine, Federal University of Minas Gerais, Belo Horizonte, Mg, Brazil.

⁵Anesthesiologist at Hospital São Camilo, Belo Horizonte, MG, Brazil

***Correspondence to:** Dr. Luiz Eduardo Imbelloni, Av. Epitácio Pessoa, 2356-Apto 203, Lagoa, 22411-072-Rio de Janeiro, RJ, Brazil. Tel: + 55.11.99429-3637.

Citation: Imbelloni LE, da Silva CHR, Vieira AdV, e Gonçalves PMS, Lopes LM (2022) Intradural And Intramedullary Melanotic Schwannoma Of The Lumbar Spine, After Spinal Anesthesia. A Case Report. Ann Clin Ane Pai Med: ACAPM-102.

Received Date: 29 June, 2022; **Accepted Date:** 04 July, 2022; **Published Date:** 11 July, 2022

Copyright: © 2022 Imbelloni LE. This is an open-access article distributed under the terms of the [Creative Commons attribution License](#), which permits unrestricted use, distribution, and reproduction in any medium, provided the original author and source are credited.

Introduction

Spinal anesthesia is one of the most used techniques in elderly patients, with doses varying according to the proposed surgery and the surgeons [1]. Schwannomas are benign, encapsulated, slow-growing neoplasms. made up of neoplastic schwann cells differentiated [2]. The most used diagnosis is magnetic resonance imaging (MRI) and confirmation is obtained through histological and immunohistochemical studies [2]. In order to study the reclassification of melanotic schwannomas (MS), a study was carried out in 40 clinicopathologic, immunohistochemical, and gene expression cases [3]. The purpose of this case report was diagnosed after the appearance of paresis in a patient undergoing urologic treatment under spinal anesthesia, two days after the procedure requiring hospitalization, and explain the possibility of performing spinal anesthesia in a patient with xanthochromic puncture.

Case Report

After written consent for publication, a male patient, 85 years old, 62 kg, 168 cm, physical status ASA II, with systemic hypertension, Parkinson's disease, urinary bladder obstruction and bladder stone, was indicated for surgical treatment. In regular use of parkidopa, epez 10 mg once a

day, enalapril 10 mg every 12 hours and torsi lax for pain management. With a surgical history of radical prostatectomy, osteosynthesis of a fracture of the right shoulder, under anesthesia without intercurrents. Laboratory tests revealed: hemoglobin 13.5 g/dL, hemotocrit 40.6%, platelets 211,000/ml, 100% prothrombin activity, INR 1.00. Normal glucose, urea and creatinine.

Elective hospitalized patient for internal urethrotomy, endoscopic bladder neck resection and removal endoscopic bladder stone. Patient referred to the surgical center with bladder catheterization. Routine monitoring electrocardiogram, heart rate (66 bpm), noninvasive pressure measurement (120x70 mmHg), pulse oximetry (97%), and was started and intravenous line (20G extracath) was placed. Intraoperatively sodium chloride solution was administered intravenously.

After sedation with midazolam (2 mg), cefazolin (2 g) intravenously and cleaning the skin with chlorhexidine, spinal anesthesia was performed, between L4-L5, sitting position, median, with 27G cutting needle. The return of CSF of xanthochrome aspect was observed (**Figure 1**), 12.5 mg of 0.5% hyperbaric bupivacaine.

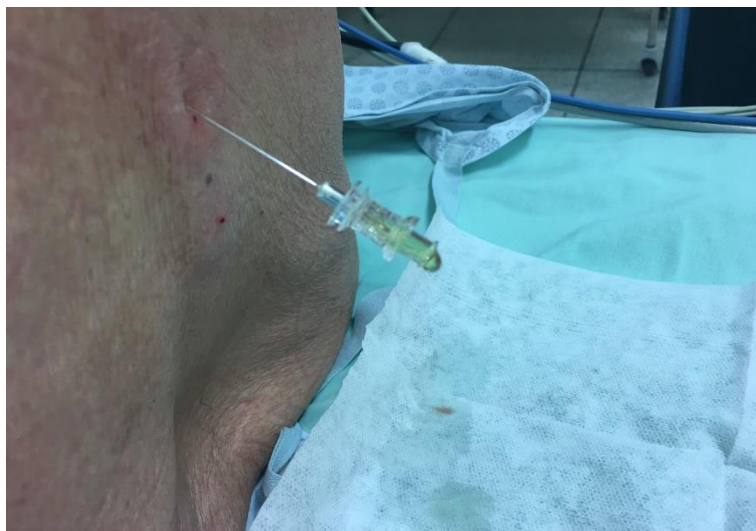

Figure 1: Photo of the patient with xanthochromic CSF in the 1st puncture.

After 10 minutes, neither analgesia below the puncture level nor any degree of motor block in the lower limbs were observed, having been considered blocking failure. A new asepsis and antisepsis procedure was performed in the sitting position, with puncture between L3-L4 with a 27G

cutting needle and hyperbaric 12.5 mg bupivacaine was injected again, with return of CSF xanthochrome aspect (**Figure 2**), and both sensory and motor blocks were installed, and the patient was released for the proposed surgery. No adjuvant was used in both spinal anesthesia.



Figure 2: Photo of the patient with xanthochromic CSF in the 2nd puncture.

The anesthetic procedure lasted 65 minutes and the surgical procedure 40 minutes, without interurrences. At the end of the procedure, the patient was referred to PACU, hemodynamically stable, awake, and cooperative. After the end of spinal anesthesia, the patient was referred to his room, with hospital discharged 24 hours after the surgical procedure.

Two days after hospital discharge, the patient returned to the hospital emergency room with a complaint of paresis in the lower limbs. Evaluated by the orthopedics and neurosurgery team who requested an MRI of the lumbosacral spine immediately. The result showed an intradural and intramedullary expansive lesion at the level of the T12-L1 vertebrae in the conus and cauda equina region measuring approximately 4.3 x 1.3 cm (**Figure 3**), and tumor resection was indicated.

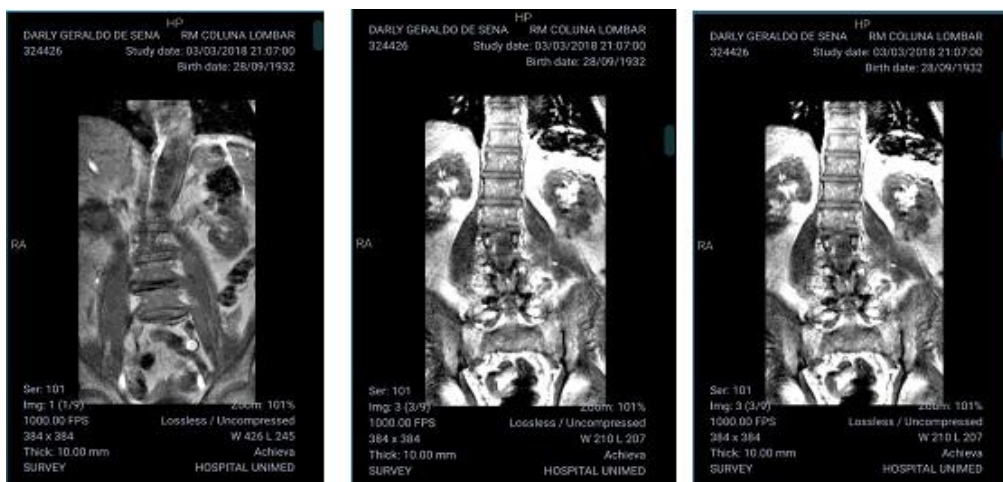


Figure 3. Three MRI two days after surgery.

Lumbosacral Spine MRI

Sagittal and axial sections showed an intradural and intramedullary expansive lesion in the conus and cauda equina region, without bone invasion. Narrow channel from L4 to S1. Reduction of intervertebral spaces. Obliteration of neuroframes of L2-L3 and L3-L4. Possible Schwannoma.

Under balanced general anesthesia, the patient underwent surgical excision of the tumor with intraoperative finding of areas of hemorrhage and melanocytic appearance. The material was sent for anatomopathological analysis indicating the histological type of melanocytic schwannoma. The patient had a good clinical evolution with hospital discharge without other complications.

Discussion

Spinal anesthesia is induced by injecting small amounts of local anesthetic into the CSF, which solution must be capable of blocking nerve paths, and non-toxic, that is, it should not hinder the proper functioning of the bulbar centers, or interfere with the metabolic processes of the more important organs. It is a very important technique and is used in elderly patients with femoral fractures [4,5] and all types of urological surgery [6]. Thus, urologic surgeries include various spectrums of disease and elderly patients, and the choice of spinal anesthesia for the endoscopic resection of the procedures is within its indications. However, the appearance of xanthochromic CSF and the failure of the first puncture were undervalued by the anesthetic team. However, the performance of the second spinal anesthesia puncture was sufficient for the surgical procedure without any intraoperative complication, with discharge to the residence 24 hours later.

We reported a case of melanocytic schwannoma, discovered on the 2nd postoperative day of urological surgery under spinal anesthesia, with the appearance of paresis, shown on MRI and confirmed after anatomopathological analysis of the surgical specimen. The most common location of the tumor is in the nerve roots, which was diagnosed based on the magnetic resonance imaging (MRI) and histopatho-

logical findings and treated with surgery [7]. Exactly what happened to our patient in this case report.

Paresis is a condition in which muscle movement is weakened. Unlike paralysis, individuals with paresis still have some control over the affected muscles. Paresis occurs due to nerve damage, which can be caused by a variety of factors or conditions [8]. There are many different factors that can cause nerve damage that results in paresis.

The composition of cerebrospinal fluid (CSF) resembles a transudate, containing approximately 99% water and small concentrations of magnesium, chlorine, glucose, proteins, amino acids, uric acid and phosphate [9]. Visual observation of CSF color and appearance is the initial step in the analysis. Liquor is normally colorless, and under certain conditions it may show changes in color, such as xanthochromic and hemorrhagic. By definition, xanthochromia is the yellow discoloration indicating the presence of bilirubin in the CSF and is used by some to differentiate in vivo hemorrhage from a lumbar puncture. There are two ways to detect xanthochromia in the CSF, being for visual inspection, but spectrophotometry increases the sensitivity of test, detecting "yellow" that is not discernible to the human eye, and can distinguish different pigments by its absorption from the light [10].

Physicians and anesthesiologists alike should bear in mind that xanthochromia unrelated to subarachnoid hemorrhage may be detected in traumatic lumbar puncture that have a high red blood cell count [11,12]. In a patient with Froin's syndrome that is characterized by marked CSF xanthochromia, he underwent a urological procedure under spinal anesthesia and later a second spinal anesthesia was performed for bladder-cancer, without complications [13].

CSF composition tests are often used to monitor brain metabolism, evaluate the functions of transport and permeability of barrier, and pharmacokinetic parameters of medicines in the brain and identify biomarkers, to help in the diagnosis and prognosis of CNS diseases [9].

Conclusion

Xanthochromia is the presence of bilirubin in the cerebrospinal fluid and is sometimes the only sign of an acute subarachnoid hemorrhage. This activity reviews the evaluation and management of xanthochromia and highlights the role of the interprofessional team in the care of patients with this condition. MS is a rare neoplasm composed of Schwann cells being usually benign, but they can become aggressive and metastatic, and their total extirpation is recommended, a conduct that occurred in this 85 -year-old patient, which was diagnosed after spinal anesthesia with appearance of xanthochromic CSF and postoperative paresis.

In the extensive search in the medical literature, only two spinal anesthesia were found in the same patient after the appearance of xanthochromic CSF in Letter to the Editor [13]. In the present case report, there were two subarachnoid punctures with the appearance of xanthochromic CSF, with a failure on the 1st attempt and success on the 2nd attempt. In this way, in the presence of xanthochromic CSF and in view of the severity of the patient's disease, the urological procedure was performed and later the diagnosis of melanotic schwannomas.

References

1. Imbelloni LE, Braga RL, Morais Filho GB, Silva A. Low dose of isobaric bupivacaine provides lower incidence of spinal hypotension for hip surgery in elderly patients. *Anaesth, Pain, Intensive Care*, 2014; 18(1): 17-20.
2. Jacob Jr C, Lugao RS, Cardoso IM et al. Melanocytic schwannoma of the lumbar spine: a case report and literature review. *Rev Med Minas Gerais*. 2015; 25(4): 616-620.
3. Torres-Mora J, Dry S, Li X et al. Malignant melanotic schwannian tumor a clinicopathologic, immunohistochemical, and gene expression profiling study of 40 cases, with a proposal for the reclassification of "Melanotic Schwannoma". *Am J Surg Pathol*. 2014; 38: 94-105.
4. Imbelloni LE, Lacerda S, Barbosa R et al. Outcome after anesthesia and surgery for fracture of the hip in patient aged over 100 years. The "oldest old" of the new millennium. *World J Pharm Pharm Sci*. 2016; 6(1): 1642-1652.
5. Imbelloni LE, Teixeira DMP, Lima U et al. Are we ready for hip fracture geriatric patients? Study with 224 patients of the fourth age. *Orthop & Spo Med Op Acc J*. 2019; 3(2): 247-254.
6. Koo CH, Ryu JH. Anesthetic considerations for urologic surgeries. *Review Article. Korean J Anesthesiol*. 2020; 73(2): 92-102.
7. Hu L, Wang C. Intramedullary melanotic schwannoma of the cervical spine: A case report and literature review. *Molecular and Clinical Oncology*. 2018; 8:567-570.
8. Seladi-Schulman J. Paresis: Types, causes, symptoms, and treatment. <https://www.healthline.com/health/paresis>. Accessed on June 6, 2022.
9. Johanson CE, Duncan III HJA, Klinge PM et al. Multiplicity of cerebrospinal fluid functions: new challenges in health and disease. *Review. Cerebrospinal Fluid Res*. 2008; 5:10: 1-32. doi:10.1186/1743-8454-5-10.
10. Graves P, Sidman R. Xanthochromia is not pathognomonic for subarachnoid hemorrhage. *Acad Emerg Med*. 2004; 11(2): 131-135.
11. Chalmers AH, Kiley. Detection of xanthochromia in cerebrospinal fluid. *Clinical Chemistry*. 1998; 44(8): 1740-1742.
12. William A. Xanthochromia in the cerebrospinal fluid. *Practical Neurology*. 2004; 4: 174-175.
13. Kwon SK, Kim MW. Pseudo-Froin's syndrome, xanthochromia with high protein level of cerebrospinal fluid. Letter to Editor. *Korean J Anesthesiol*. 2014; 67(Suppl): S58-S59.